



Original Article

Optimal doses and neuroprotective effects of prolonged treatment with young coconut juice in orchidectomized rats. A preliminary study

Tatcha Balit¹, Asma Asae¹, Piyakorn Boonyoung¹, Kanyaphak Chanchula¹, Phetai Hiranphan², Thammarat Panityakul³, and Nisaudah Radenahmad^{1*}

¹ Department of Anatomy, Faculty of Science, Prince of Songkla University, Hat Yai, Songkhla, 90110 Thailand

² Department of Physiology, Faculty of Science, Prince of Songkla University, Hat Yai, Songkhla, 90110 Thailand

³ Department of Mathematics and Statistics, Faculty of Science, Prince of Songkla University, Hat Yai, Songkhla, 90110 Thailand

Received: 28 June 2016; Revised: 19 January 2017; Accepted: 23 January 2017

Abstract

Our previous studies showed that feeding of young coconut juice (YCJ) had beneficial effects in both male and female rats such as preventing osteoporosis, accelerating wound healing and delaying Alzheimer's disease (AD) pathologies. Nevertheless, this large dose of YCJ feeding for five weeks in female rats started to have unfavorable side effects e.g. the deposition of glycogen in the liver. Thus, our aim in the present study was to investigate the lowest neuroprotective dose of YCJ that would cause the least side effects for long-term consumption in male rats. Three low doses of YCJ (10, 20 and 40 mL/kg body weight (BW) were applied. The results showed that YCJ preserved the number of neuronal cells but to different degrees in each area of the brain. After 10 weeks of treatment, the BW and organ weights (liver, kidney and adrenal gland) of the three YCJ treated groups were not significantly different from the control group. Moreover, the circulating levels of blood sugar, cholesterol, triglyceride, HDL, BUN, creatinine, total protein, albumin, AST, ALT, alkaline phosphatase, sodium, calcium, phosphorus and magnesium of the three YCJ treatments were not significantly different from the sham group. These results indicated that YCJ consumption might have potential to be a supplement for preserving neuronal cell density and was safe in terms of lipid, liver and renal profiles.

Keywords: young coconut juice, *Cocos nucifera*L., Areaceae, cresyl violet staining, orchidectomy, serum chemical analysis

1. Introduction

Although the prevalence and incidence of Alzheimer's disease (AD) are higher in women, men have also a robust age-related increase risk of AD (Feldman *et al.*, 2002). In advancing age, men have a significant decrease of androgen levels (Morley *et al.*, 1997) and androgen therapy can lower the

risk of AD but also increases the risk of adverse effects such as stroke, heart attack, prostate cancer (Finkle *et al.*, 2014) and reduction of HDL-cholesterol levels (Isidori *et al.*, 2005). In a previous study it was shown that estrogen has beneficial effects on cognitive performance (Beer *et al.*, 2006), maintains bone formation (Falahati-Nini *et al.*, 2000) and plays an important role in cardiovascular effects in men (Sharpe, 1998). In a rodent model estrogen reduced the risk of AD in the hippocampus CA1 in male rats (Rosario *et al.*, 2010). Although estrogen replacement therapy has several benefits, it causes gynecostasia in men (Chen *et al.*, 2015) and can be involved in the

*Corresponding author
Email address: nisaudah.r@psu.ac.th

induction of prostate cancer (Soronen *et al.*, 2004). Therefore plant-derived phytoestrogens, have been used to replace estrogen. Young coconut juice (YCJ) known to contain the phytoestrogen, β -sitosterol (Rattanaburee *et al.*, 2014) has several beneficial effects such as preventing osteoporosis (Yusuh *et al.*, 2010), accelerating wound healing (Radenahmad *et al.*, 2014; 2015) and delaying AD pathologies in ovariectomized rats (Radenahmad *et al.*, 2009; 2011). Nevertheless, such a large dose of YCJ feeding for five weeks started to have unfavorable side effects e.g. the deposition of glycogen in the liver (Payanglee *et al.*, 2016).

With this background, three lower doses of YCJ were used to find the optimal neuroprotective dose for use in hormone replacement therapy (HRT) treatment using orchidectomized (orx) rats as a model for andropausal men. Therefore, our aim in the present study was to investigate the lowest neuroprotective dose of YCJ that would cause the least side effects for long-term consumption by andropausal men using orx rats, as a model.

2. Materials and Methods

2.1 YCJ preparation

A large volume of young coconut juice (*Cocos nucifera* L., Arecaceae) was collected from Khlong Hoi Khong district, Hat Yai, Songkhla, Thailand, dried, and the powder form kept at $-30\text{ }^{\circ}\text{C}$ until used. This powder was freshly reconstituted and prepared for oral intake every day. A complete description of YCJ, including its preparation and administration, has been provided in our previous publications (Radenahmad *et al.*, 2006).

2.2 Animals

All animals used were adult eight-month old, male Wistar rats weighing 250-300 g. The rats were housed in a controlled environment at $25\pm 1\text{ }^{\circ}\text{C}$ on an illumination schedule of a 12 hr light-12 hr dark cycle, with unrestricted access to standard pellet food and water. The study was approved by the Committee on Animal Care, and was carried out in accordance with the Guiding Principles for the Care and Use of Research Animals promulgated by the Prince of Songkla University. The license number is 01/2016.

2.3 Experimental design

Rats were randomly divided into seven groups (10 rats per group): the control baseline rats (bl); sham-operated rats receiving vehicle (sd); orchidectomized (orx) rats receiving vehicle (od); orx injected with exogenous estrogen ($2.5\text{ }\mu\text{g}/\text{kg}$ BW of estradiol benzoate, EB) three days a week for 10 weeks (oe); and three groups of orx rats that receiving YCJ at 10, 20 and 40 mL/kg BW/day (oy10, oy20 and oy40), respectively, for ten weeks. The dose of EB was also the same as in our earlier study (Radenahmad *et al.*, 2006). YCJ feeding and EB injection were started one week after performing orchidectomy. After 10 weeks, the rats were sacrificed and the brains, liver, kidney, adrenal gland, prostate glands and seminal vesicles were removed, weighed, fixed and paraffin embedded for sectioning and staining. Their serum was collected for blood sugar, cholesterol, triglyceride, HDL, LDL, BUN, creatinine, total

protein, albumin, AST, ALT, alkaline phosphatase, Na^+ , K, Ca^{2+} , P and Mg^{2+} measurements.

2.4 Cresyl violet staining of the brains and morphological analysis

Tissue samples from the prefrontal cortex (PF) and the hippocampus (HP) were processed into paraffin blocks and cut at 5 μm -thick coronal brain sections. The sections were stained with cresyl violet and were used for light microscopic examination and anatomical orientation. The total number of neuronal cells from PF and HP were counted at 40x magnification. Counting was carried out on ten random fields. Data was expressed as the mean number of neuronal cells per mm^2 .

2.5 Hematoxylin & Eosin (H&E) staining of seminal vesicles and prostate glands

The seminal vesicle and prostate gland blocks were cut at a 5 μm thickness and were stained with H&E to investigate the effects of hormones on any histopathological changes.

2.6 Statistical analysis

The data were expressed as a mean value and the standard error of the mean ($\text{mean}\pm\text{SEM}$). Statistical analysis was performed using the One-way ANOVA followed by the LSD test to compare the mean of one group with the mean of another. $P<0.05$ was accepted as being significant.

3. Results and Discussion

3.1 Histopathological assessment of neuronal cells

Cresyl violet was used to demonstrate the Nissl substance in the neurons and cell nuclei (Figure 1). In the present study, the numbers of neuronal cells in the PF and HP (CA1, CA2 and CA3) of the od group were significantly lower than those of the control groups (bl, sd and oe). The number of neuronal cells in the orx groups orally force fed with YCJ was preserved at different degrees in each area (Table 1). For example, in the PF area, the number of neuronal cells of the oy40 group was the highest among the three doses of YCJ feeding and that was significantly higher than that in the bl and the od groups. In the CA1 and CA2 areas, the numbers of neuronal cells were significantly higher than those of the od group in all the 3 doses of YCJ feeding (oy10, oy20 and oy40). In the CA3 area, the numbers of neuronal cells of the oy10 and the oy40 groups were higher than those of the control groups, including the od group, while that of the oy20 group was significantly lower than that of the sd group. This study demonstrated that all 3 doses of YCJ could preserve neuronal cells in PF, HP (CA1, CA2 and CA3), the areas that play a critical role in learning and memory (Mu & Gage, 2011). In contrast, a decline in neurogenesis may underline cognitive impairment associated with aging and disorders such as AD (Clelland *et al.*, 2009; Lazarov *et al.*, 2010). These results confirmed our previous studies in female rats that YCJ has phytoestrogen-like effects to neuroprotect and to prevent neuronal cell death by delaying AD pathologies (Radenahmad

et al., 2009; 2011). The experiments of Morito demonstrated that phytoestrogens were able to bind ER α and ER β (Morito *et al.*, 2001) and led to activation of transcriptional expression and neuronal cell growth (Pilsakova *et al.*, 2010). Immunohisto-

chemistry for specific neuronal markers and estrogen receptors of both types (ER α and ER β) had also been studied to confirm these phenomena. That manuscript has been separately prepared due to the large amount of data involved.

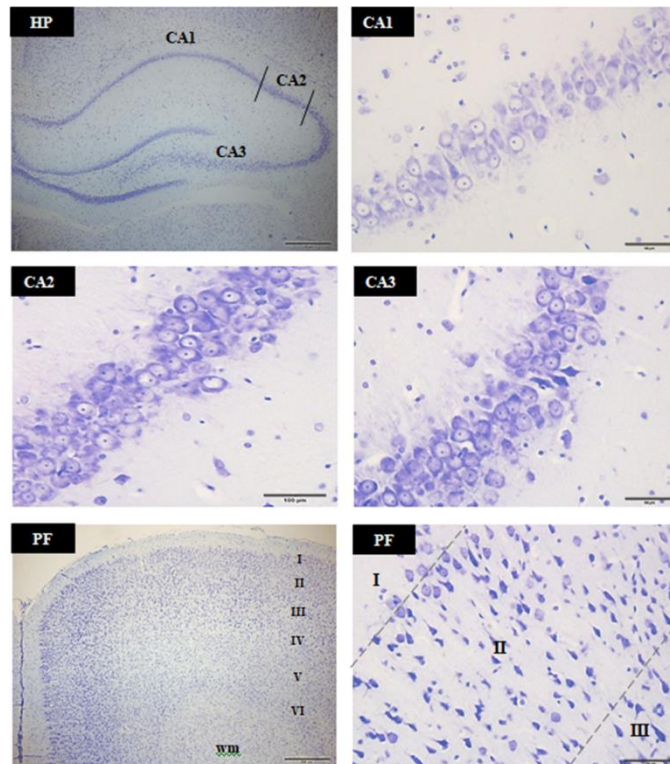


Figure 1. Histology of the hippocampus (CA1, CA2, CA3) and prefrontal cortex (PF): Expression of the cresyl violet positive neurons in the hippocampal areas of CA1, CA2, CA3, and PF (prefrontal cortex) of the bottom right: in all areas of hippocampus (HP): CA1, CA2, CA3, and PF, the numbers of neuronal cells of the od group were the lowest and significantly lower than the control (bl, sd and oe groups) and all 3 doses of YCJ treatment (oy10, oy20 and oy40 groups) groups. Surprisingly, the numbers of neuronal cells of the oe and oy20 groups of CA3 hippocampus were lower than the number of the sd group. In the PF area, the numbers of neuronal cells of the oy40 group were the highest and that were significantly higher than for the bl and the od groups. x40magnification; HP and PF of the bottom left: overview photos: x4magnification. wm = white matter.

Table 1. Neuronal cell density: Numbers of neuronal cells (pyramidal and glial cells) stained by cresyl violet (mean \pm SEM) in the hippocampal areas: CA1, CA2 and CA3 of the 7 groups of rats examined, n = 10 per group. PF = prefrontal cortex. bl= baseline group, sd = sham-operated group, od = orchidectomized group, oe =orchidectomized group receiving estradiol benzoate, oy10 = orchidectomized rats receiving YCJ 10 mL/kgBW/day, oy20 = orchidectomized rats receiving YCJ 20 mL/kgBW/day, oy40 = orchidectomized rats receiving YCJ 40 mL/kgBW/day. ^a p<0.05 compared with the bl group. ^b p<0.05 compared with the sd group. ^c p<0.05 compared with the od group. ^d p<0.05 compared with the oe group.

Groups	bl (n=10)	sd (n=10)	od (n=10)	oe (n=10)	oy10 (n=10)	oy20 (n=10)	oy40 (n=10)
CA1	47.65 \pm 2.37	46.18 \pm 1.99	34.63 \pm 1.10 ^{a,b}	43.49 \pm 2.41 ^c	42.60 \pm 1.16 ^c	46.68 \pm 1.92 ^c	47.71 \pm 1.85 ^c
CA2	48.87 \pm 2.75	49.40 \pm 3.74	34.07 \pm 0.51 ^{a,b}	44.27 \pm 2.45 ^c	43.30 \pm 1.85 ^c	45.00 \pm 1.10 ^c	46.73 \pm 3.49 ^c
CA3	40.74 \pm 1.54	43.44 \pm 3.19	29.31 \pm 1.27 ^{a,b}	37.05 \pm 1.85 ^{b,c}	42.26 \pm 2.80 ^c	36.61 \pm 0.81 ^{b,c}	42.03 \pm 2.51 ^c
PF	50.50 \pm 2.08	52.32 \pm 1.15	43.34 \pm 1.14 ^{a,b}	53.39 \pm 0.95 ^c	52.41 \pm 2.50 ^c	53.30 \pm 1.48 ^c	55.15 \pm 1.24 ^{a,c}

3.2 Body weight

After orx for 10 weeks, the body weight (BW) of the oe group on the day of termination was significantly lower than that on the day of commencement (Table 2). The present result indicated that the deficiency of testosterone after orx and supplementing with estrogen by injection with EB in the oe group could help to reduce the body weight. The present result is in agreement with Pratchayasakul who found that the body weight of both normal and high fat diet male mice treated with

estrogen was significantly lower than that of the vehicle treatment group (Pratchayasakul *et al.*, 2011). The body weight of all the 3 OY groups (oy10, oy20 and oy40) was lower, even though statistically was not significant shown when compared between the commencement day and the last day of the experimental force feeding with YCJ for 10 weeks. This indicated that YCJ might not affect the accumulation of fat in orx rats, even though YCJ contained a very high percentage 44.9% of glucose and 43.9% of fructose (Santoso *et al.*, 1995) and these might be converted to glycogen in liver or to fat in the body.

Table 2. Body weight and %age organ weight/body weight (BW): Body weight (g) and the %age of brain, liver, kidney, seminal vesicle, prostate gland, adrenal gland, heart and aorta (mean \pm SEM) of the 7 groups of rats examined, bl = baseline group, sd = sham-operated group, od = orchidectomized rats, oe = orchidectomized rats + estradiol benzoate (EB), oy10 = orchidectomized rats receiving YCJ 10 mL/kgBW, oy20 = orchidectomized rats receiving YCJ 20 mL/kgBW, oy40 = orchidectomized rats receiving YCJ 40 mL/kgBW. * $p < 0.05$ comparison between the body weight at the commencement of the study and the day that the rats were terminated. ^a $p < 0.05$ compared with the bl group. ^b $p < 0.05$ compared with the sd group. ^c $p < 0.05$ compared with the od group. ^d $p < 0.05$ compared with the oe group.

Parameters	bl (n=10)	sd (n=10)	od (n=10)	oe (n=10)	oy10 (n=10)	oy20 (n=10)	oy40 (n=10)
BW Started	552.60 \pm 32.69	540.70 \pm 28.82	530.00 \pm 27.33	571.70 \pm 32.50	520.50 \pm 22.14	504.70 \pm 21.58	485.30 \pm 21.06
BW finished	552.60 \pm 32.69	528.20 \pm 17.53	493.80 \pm 17.69	489.30 \pm 19.94 ^a	511.70 \pm 21.12	485.10 \pm 16.95	473.40 \pm 15.04
Brain	0.38 \pm 0.02	0.40 \pm 0.01	0.43 \pm 0.01 ^a	0.43 \pm 0.01 ^a	0.41 \pm 0.01 ^a	0.43 \pm 0.01 ^a	0.44 \pm 0.01 ^{ab}
Liver	2.74 \pm 0.09	2.35 \pm 0.08 ^a	2.54 \pm 0.08	2.73 \pm 0.12 ^b	2.26 \pm 0.05 ^{a,c,d}	2.26 \pm 0.05 ^{a,c,d}	2.25 \pm 0.07 ^{a,c,d}
Kidney	0.52 \pm 0.03	0.48 \pm 0.01 ^a	0.47 \pm 0.01 ^a	0.52 \pm 0.01 ^c	0.46 \pm 0.01 ^{ad}	0.46 \pm 0.01 ^{ad}	0.46 \pm 0.01 ^{ad}
Seminal vesicle	0.21 \pm 0.03	0.17 \pm 0.01	0.04 \pm 0.00 ^{ab}	0.04 \pm 0.00 ^{ab}	0.04 \pm 0.00 ^{ab}	0.06 \pm 0.03 ^{ab}	0.04 \pm 0.00 ^{ab}
Prostate gland	0.12 \pm 0.02	0.12 \pm 0.02	0.03 \pm 0.00 ^{ab}	0.03 \pm 0.01 ^{ab}	0.02 \pm 0.00 ^{ab}	0.02 \pm 0.00 ^{ab}	0.02 \pm 0.00 ^{ab}
Adrenal gland	0.02 \pm 0.00	0.03 \pm 0.00 ^a	0.03 \pm 0.00 ^a	0.03 \pm 0.00 ^a	0.03 \pm 0.00 ^a	0.03 \pm 0.00 ^a	0.03 \pm 0.00 ^a
Heart	0.30 \pm 0.01	0.31 \pm 0.01	0.31 \pm 0.01	0.31 \pm 0.01	0.30 \pm 0.01	0.31 \pm 0.28	0.31 \pm 0.01
Aorta	0.03 \pm 0.00	0.05 \pm 0.00 ^a	0.04 \pm 0.01	0.05 \pm 0.01 ^a	0.04 \pm 0.01	0.04 \pm 0.01	0.04 \pm 0.00

3.3 %organ weight/body weight

3.3.1 %brain weight/BW

The %ages brain/BW of the od, oe, oy10, oy20 and oy40 groups were significantly higher than that of the bl group but not significantly different from the sd group except for the oy40 group (Table 2), indicating that aging, the deficiency of testosterone (od group) and/or supplementation with exogenous estrogen (oe group) or with phytoestrogen (in the oy10 and oy20 groups) did not significantly affect the brain weights. This is consistent with Skullerus (Skullerus, 1985) who found that human brain autopsies showed shrinkage starting after the age of 55, and the rat brains in the present study were of an age equivalent to about 40 years old human brains. Skullerus demonstrated that in the case of neurodegenerative brain such as Alzheimer's disease, the reduction of brain weight occurred in old women but not in old men (Skullerus, 1985). Furthermore, White proved a significant and independent association in higher midlife tofu consumption with poor cognitive test performance, enlargement of ventricles and low human brain weight (White *et al.*, 2000).

3.3.2 %liver weight/BW

That %liver weight/BW of the oe group was significantly higher than that of the sd group. For all three doses of YCJ feeding group (oy groups) the %liver weight/BW was significantly lower than that of the bl, od and oe groups. This implied that exogenous estrogen (oe group) might increase the liver weight. On the other hand, feeding with YCJ did not increase liver weight. This might imply that YCJ-phytoestrogen had no effect on liver weight. The present results are in agreement with Manasathien (2001), who found that 7-week-old male mice treated with Red KwaoKreua for three and six weeks had no changes to liver morphology and the liver weight when compared with the control group. So the three different doses of YCJ supplementation (10, 20 and 40 mL/kgBW) in orx rats caused no harm to the liver.

3.3.3 %kidney weight/BW

The %ages of the kidney weight/BW of the YCJ feeding groups (oy10, oy20, oy40) was significantly lower than that of the bl and oe groups. In contrast, the %age for the oe

group was significantly higher than that of the od group. This implies that exogenous estrogen (oe group) might cause a gain in kidney weight. On the other hand, feeding with YCJ did not raise kidney weight. This is consistent with the study by Manasathien (Manasathien, 2001) who found that a 7 week-old male mice treated with Red Kwao Krea containing flavonoid for three and six weeks had no changes of kidney morphology and the kidney weight comparing to the control group. In addition, Velasquez investigation demonstrated that the biochemistry, metabolism, and mechanisms of actions of isoflavones and lignans appear to act through various mechanisms that modulate cell growth and proliferation, extracellular matrix synthesis, inflammation, and oxidative stress to control normal function in kidney (Velasquez *et al.*, 2001). So, this might imply that YCJ-phytoestrogen did not affect renal weight. Thus, YCJ supplementation in orx rats caused no harm to the kidneys.

3.3.4 %seminal vesicle and prostate gland weight/BW

The %ages of the seminal vesicle and prostate gland

weight/BW of the od, oe and all of the three oy groups were significantly lower when compared with the bl and sd groups. These results are consistent with the study by Rosario (Rosario *et al.*, 2010) that showed that the seminal vesicle weight of three months orx mice treated/ not treated with EB were not significantly different from the control group. The weights of the seminal vesicle and prostate gland decreased due to the reduction of the androgen level in the od, oe and oy groups caused by the orchidectomy (orx). Furthermore, no histopathological changes were shown in any of the three oy groups compared with the od and oe groups and that changes were dramatically reduced when compared with the bl and sd groups (Figures 2 and 3). This implies that the seminal vesicle and prostate gland are androgen dependent organs and supplementation with exogenous estrogen (oe group) or YCJ-phytoestrogen (oy groups) caused organs neither to gain weight nor undergo any histopathological changes. This is in agreement with many other studies and confirms that phytoestrogen is associated with a decreased risk of prostate cancer (Adlercreutz, 1995; Hedelin *et al.*, 2006). Therefore, those three doses of YCJ supplementation in orx rats produced no harm to the prostate gland and seminal vesicle.

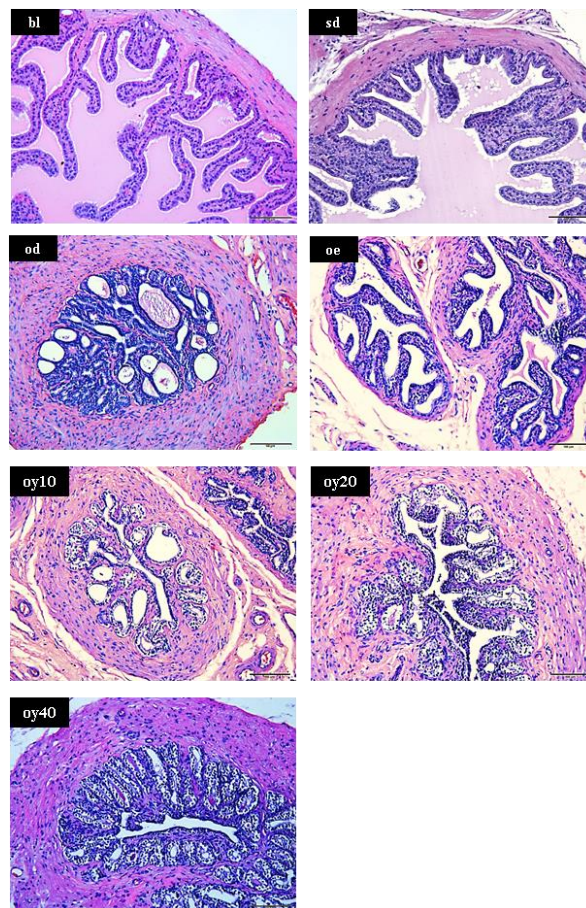


Figure 2. Histology of seminal vesicle: Hematoxylin-eosin staining of seminal vesicle tissue of 5 μm thick, paraffin sections, from the 7 groups of rats examined, x20 magnification. In all 3 oy groups, histopathological changes were obviously reduced when compared with the bl and sd groups and no changes were observed when compared with the od and the oe groups. bl= baseline group, sd = sham-operated group, od = orchidectomized group, oe =orchidectomized group receiving estradiol benzoate, oy10 = orchidectomized rats receiving YCJ 10 mL/kgBW/day, oy20 = orchidectomized rats receiving YCJ 20mL/kgBW/day, oy40 = orchidectomized rats receiving YCJ 40 mL/kgBW/day.

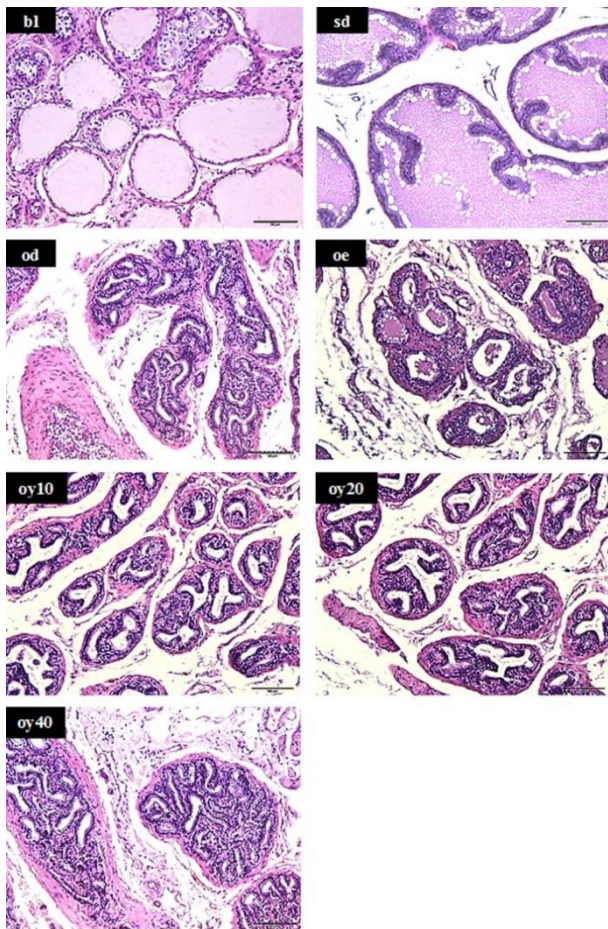


Figure 3. Histology of prostate gland: Hematoxylin-eosin staining of 5 μ m thick paraffin sections, of prostate gland tissue from the 7 groups of rats examined, x20 magnification. In all 3 oy groups, histopathological changes were obviously reduced when compared with the bl and sd groups and no changes were shown when compared with the od and the oe groups. bl= baseline group, sd = sham-operated group, od = orchidectomized group, oe =orchidectomized group receiving estradiol benzoate, oy10 = orchidectomized rats receiving YCJ 10 mL/kgBW/day, oy20 = orchidectomized rats receiving YCJ 20mL/kgBW/day, oy40 = orchidectomized rats receiving YCJ 40 mL/kgBW/day.

3.3.5 %adrenal gland weight/BW

The %adrenal gland weight/BW of the bl group was significantly lower than that in all the other groups. This indicates that the adrenal gland weight was increased by aging. This result was also in accordance with those from Manasathein(Manasathein, 2001),who found that a 7 week-old male mice treated with Red Kwao Krea for three and six weeks, showed no changes of adrenal gland morphology and the adrenal gland weight in the treatment groups compared to the control group. In addition, values of the oe and oy groups were not significantly different from the sd group. This implies that supplementation with exogenous estrogen (oe group) and YCJ in orx rats caused no harm to the adrenal gland.

3.3.6 %heart weight/BW

The %heart weight/BW of all groups was not significantly different when compared to each other. This might imply that YCJ treatment in the present study did not cause any changes of gross weight as there were no changes of heart functions found. This result is in accordance with those from Bhupathy (Bhupathy *et al.*, 2010), who demonstrated that heart tissue has estrogen receptors (ERs) α and β , and that they can bind with phytoestrogens. When phytoestrogens bind with ERs, they can activate normal functions of heart. For example, isoflavones have been shown to induce vasodilation by stimulating the activity of the endothelial NO synthase 3 (NOS 3). Genistein and daidzein decrease monocyte chemoattractant protein-1 and collagen-induced platelet aggregation in a dose-dependent manner, indicating that phytoestrogens could act as antithrombotic and antiatherogenic agents. This implies that YCJ supplementation in orx rats caused no harm to the heart.

3.3.7 %aorta weight/BW

The %aorta weight/BW of the sd and oe groups were significantly higher than that of the bl group. This implies that the aorta weight was increased by aging and supplementation of orx rats with exogenous estrogen (oe group) caused aorta weight gain. In contrast, supplementation with YCJ in orx rats caused no increase of aorta weight. Supplementation with YCJ in orx rats could be summarized at the present caused no harm to the aorta. Cardioprotective effects of estrogen are assumed to be exerted via different partway, such as inducing mitochondrial biogenesis; directly or indirectly upregulating cardioprotective genes including PGC-1 α , MCIP1 and HSP72; activating nitric oxide synthase and Akt through the P13 kinase pathway and upregulating the production of cardiac natriuretic hormones. There is still a lack of reliable studies of testosterone and its mechanism(s) of action in the heart (Bhupathy *et al.*, 2010). Since the present study is the first study of YCJ in male rats, the underlying mechanisms of YCJ still need to be explored in the future.

3.4 Serum chemical analysis

The serum levels of blood sugar of the oy40 group were the lowest and significantly lower than that of the bl and od groups. The serum cholesterol, triglyceride, and HDL values of all three YCJ feeding groups were significantly lower than that the oe group and those three parameters of the oe group were the highest. In contrast, the serum LDL of the oy40 group was the highest. The serum LDL of the oy10 and oy40 groups was significantly higher than the sd group. It was of interest that the serum levels of cholesterol, triglyceride and HDL of the orx rats receiving EB 2.5 μ g/kgBW (oe group) were the highest. These results are inconsistent with many studies e.g. daidzein and genistein caused a reduced blood sugar level (Andreoli *et al.*, 2015), had anti-obesity effects (Bhathena *et al.*, 2002), reduced lipid profiles including cholesterol (Sosic-Jurjevic *et al.*, 2007), and preserved LDL, HDL and triglyceride levels (Amani *et al.*, 2004). Also β -sitosterol reduced the removal of cholesterol from the plasma membrane into the cell leading to a reduction of cell cholesterol. In addition, β -sitosterol decreased the expression of the HMG-CoA reductase gene that is needed for cholesterol synthesis (Field *et al.*, 1997). β -

sitosterol is a major component of YCJ (Ratanaburee *et al.*, 2014). Thus, it is possible that YCJ could improve lipid profiles in the present study because of their β -sitosterol content.

The serum levels of BUN, creatinine, total protein, albumin, AST, ALT, alkaline phosphatase, sodium, potassium, calcium, phosphorus and magnesium of all 3 YCJ treatment groups (oy10, oy20 and oy40 groups) were not significantly different from those of the sd group, except that the serum potassium level of the oy40 group was significantly higher than that of the sd group. These data are consistent with the decreasing hepatic dysfunction parameters studied by Hamden (Hamden *et al.*, 2009), preserving renal function in male rats

and controlling electrolyte balance investigated by Ogborn *et al.* (1999).

Among other active compounds of YCJ that could potentially influence lipid levels would be amino-acid L-arginine. Beta-sitosterol the major components of YCJ (Ratanaburee *et al.*, 2014) is another possibility that could explain the lowering effect of the lipid parameters (please see details in “the discussion” section of Radenahmad *et al.*, 2016). Another possibility was that YCJ could decrease the serum level of triglyceride in rats fed with coconut water by increasing the activity of a lipoprotein lipase in the heart and adipose tissue (Sandhya & Rajamohan 2008).

Table 3. Serum chemical analysis (mean \pm SEM) of the 7 groups of rats examined. bl = baseline group, sd = sham-operated group, od = orchidectomized rats, oe = orchidectomized rats + estradiol benzoate (EB), oy10 = orchidectomized rats receiving YCJ 10 mL/kgBW, oy20 = orchidectomized rats receiving YCJ 20 mL/kgBW, oy40 = orchidectomized rats receiving YCJ 40 mL/kgBW, HDL = high density lipoprotein, LDL = low density lipoprotein, BUN = blood urea nitrogen, AST = aspartate aminotransferase, ALT = alanine aminotransferase. ^a p<0.05 compared with the bl group. ^b p<0.05 compared with the sd group. ^c p<0.05 compared with the od group. ^d p<0.05 compared with the oe group, ^e p<0.05 compared with the oy10 group and ^f p<0.05 compared with the oy20 group.

Parameters	Groups						
	bl(n=10)	sd(n=10)	od (n=10)	oe (n=10)	oy10 (n=10)	oy20 (n=10)	oy40 (n=10)
Blood sugar (mg/dL)	118.7 \pm 8.95	106.1 \pm 4.11	119.9 \pm 5.86	99 \pm 6.99 ^{a,c}	102.8 \pm 7.97	108.8 \pm 7.38	93.5 \pm 5.86 ^{a,c}
Cholesterol (mg/dL)	63.5 \pm 3.6	58.1 \pm 3.49	69.1 \pm 5.05	94 \pm 12.68 ^{a,b,c}	71.3 \pm 6.76 ^d	69.3 \pm 3.47 ^d	72 \pm 4.20 ^d
Triglyceride (mg/dL)	97.7 \pm 7.48	78.3 \pm 7.92	84 \pm 10.07	220.5 \pm 89.14 ^{a,b,c}	68.3 \pm 9.51 ^d	89.2 \pm 18.08 ^d	55.8 \pm 4.34 ^d
HDL (mg/dL)	26.3 \pm 1.36	22.4 \pm 1.86	26.5 \pm 2.59	35 \pm 3.53 ^{a,b,c}	27.5 \pm 2.26 ^d	25.8 \pm 1.53 ^d	25.2 \pm 1.84 ^d
LDL (mg/dL)	17.5 \pm 3.37	20.1 \pm 3.07	25.56 \pm 2.93	27.67 \pm 4.19 ^a	30.2 \pm 4.19 ^{a,b}	29.2 \pm 2.09 ^a	35.6 \pm 3.12 ^{a,b,c}
BUN (mg/dL)	19.4 \pm 0.83	19.9 \pm 1.23	21.2 \pm 1.35	19.2 \pm 0.81	19.2 \pm 0.89	18.9 \pm 0.69	18.7 \pm 1.08
Creatinine (mg/dL)	0.81 \pm 0.09	0.93 \pm 0.13	0.77 \pm 0.03	0.81 \pm 0.07	0.82 \pm 0.05	0.88 \pm 0.11	0.92 \pm 0.13
Total protein (g/dL)	7.4 \pm 0.12	7.26 \pm 0.52	7.09 \pm 0.10	7.43 \pm 0.15	7.41 \pm 0.14	7.62 \pm 0.15	7.72 \pm 0.17
Albumin (g/dL)	3.21 \pm 0.08	3.14 \pm 0.18	2.96 \pm 0.03	3.13 \pm 0.07	3.02 \pm 0.07	3.12 \pm 0.11	3.16 \pm 0.10
AST (U/L)	277.20 \pm 29.02	253 \pm 23.90	284 \pm 20.01	304.90 \pm 33.53	327.80 \pm 30.49	294.90 \pm 26.30	309.50 \pm 34.64
ALT (U/L)	109 \pm 6.19	127.50 \pm 10.51	100.30 \pm 5.64 ^b	103.60 \pm 8.05	119.70 \pm 7.56	126.40 \pm 13.89 ^c	124.70 \pm 6.79
Alkaline phosphatase (U/L)	157.50 \pm 10.52	120.10 \pm 13.62 ^a	153.20 \pm 15.12	106 \pm 10.80 ^{a,c}	125.60 \pm 14.94	140.60 \pm 15.16	152.50 \pm 10.63 ^d
Sodium (mmol/L)	95.98 \pm 26.89	141.25 \pm 1.10 ^a	140.38 \pm 0.80 ^a	140.25 \pm 092 ^a	140.88 \pm 1.02 ^a	141.50 \pm 0.46 ^a	140.63 \pm 0.68 ^a
Potassium (mmol/L)	7.63 \pm 0.24	6.89 \pm 0.09 ^a	8.41 \pm 0.29 ^{a,b}	8.21 \pm 0.30 ^b	7.05 \pm 0.08 ^{c,d}	7.19 \pm 0.16 ^{c,d}	7.96 \pm 0.27 ^{b,e,f}
Calcium (mg/dL)	10.20 \pm 0.15	9.84 \pm 0.10 ^a	9.84 \pm 0.13 ^a	9.93 \pm 0.05	10.08 \pm 0.07	10.03 \pm 0.12	10.11 \pm 5.78
Phosphorus (mg/dL)	7.06 \pm 0.50	6.06 \pm 0.11	5.33 \pm 0.25 ^a	5.31 \pm 0.32 ^a	5.86 \pm 0.16 ^a	5.34 \pm 0.27 ^a	5.78 \pm 0.22 ^a
Magnesium (mg/L)	21.50 \pm 0.29	24 \pm 0.60	24.25 \pm 0.65 ^a	23.88 \pm 0.55	23.38 \pm 0.53	23.75 \pm 0.84	23.13 \pm 1.37

4. Conclusions

In summary, this preliminary study has illustrated that YCJ fed at 10 mL/kg body weight per day, which is equal to the consumption of one coconut per day, was the optimal dose in terms of preserving neuronal cell density and serum markers for lipid, liver, kidney, electrolytes as well as blood sugar. None of the 3 YCJ feeding doses, however, had any effect on the male hormone target organs including the seminal vesicles, prostate gland and adrenal gland. These results indicate that YCJ consumption probably could be used for preserving neuronal cell density in PF and HP, the brain areas involved with learning and memory in orx rats, a model for andropausal men and it was also safe in terms of lipid, liver and renal profiles. A research trial in human would be hopefully conducted in the near future.

Acknowledgements

We thank Dr B. Hodgson from the Faculty of Pharmaceutical Science, Prince of Songkla University for correction and improvement of the manuscript. This work was supported by the government budget of the Prince of Songkla University, GRANT CODE: SCI590730S.

References

- Adlercreutz, H. (1995). Phytoestrogen: Epidemiology and a possible role in cancer protection. *Environmental Health Perspectives*, 103, 103-112.
- Amani, R., Zand-Moghaddam, A., Jalali, M. T., & Hata mizadeh, M. A. (2004). Effects of soy protein isoflavones on lipid profile and serum hormones in hypercholesterolemic men. *International Journal of Endocrinology and Metabolism*, 2, 29-34.
- Andreoli, M. F., Stoker, C., Rossetti, M. F., Alzamendi, A., Castrogiovanni, D., Lague, E. H. & Ramos, J. G. (2015). Withdrawal of dietary phytoestrogen in adult male rats affects hypothalamic regulation of food intake, induces obesity and alters glucose metabolism. *Molecular and Cellular Endocrinology*, 401, 111-119.
- Beer, T. M., Bland, L. B., Bussiere, J. R., Neiss, M. B., Wersinger, E. M., Garzotto, M., . . . Janowsky, J. S. (2006). Testosterone loss and estradiol administration modify memory in men. *The Journal of Urology*, 175, 130-135.
- Bhathena, S. J., & Velasquez, M. T. (2002). Beneficial role of dietary phytoestrogens in obesity and diabetes¹. *The American Journal of Clinical Nutrition*, 76, 1191-1201.
- Bhupathy, P., Haines. C. D., & Leinwand, L. A. (2010). Influence of sex hormones and phytoestrogens on heart disease in men and women. *Women's health (London, England)*, 6, 77-95.
- Chen, Z., Wang, O., Nie, M., Elison, K., Zhou, D., Li, M., . . . Xing, X. (2015). Aromatase deficiency in a Chinese adult man caused by aromatase deficiency in a Chinese adult man caused by novel compound heterozygous CYP19A1 mutations: Effects of estrogen replacement therapy on the bone, lipid, liver and glucose metabolism. *Molecular and Cellular Endocrinology*, 399, 32-42.
- Clelland, C. D., Choi, M., Romberg, C., Clemenson, G. D., Fragniere, A., Tyers, P., . . . Gage, F. H. (2009). A function role of adult hippocampus neurogenesis in spatial pattern separation. *Trends in Neurosciences*, 33, 569-579.
- Falahati-Nini, A., Riggs, B. L., Atkinson, E. J., O'Fallon, W. M., Eastell, R., & Khosla, S. (2000). Relative contributions of testosterone and estrogen in regulating bone resorption and formation in normal elderly men. *The Journal of Clinical Investigation*, 12, 1553-1560.
- Feldman, H. A., Longcope, C., Derby, C. A., Johannes, C. B., Araujo, A. B., Coviello, A. D., . . . McKinlay, J. B. (2002). Age trends in the level of serum testosterone and other hormones in middle-aged men: longitudinal results from the Massachusetts male aging study. *The American Journal of Clinical Nutrition*, 87, 589-598.
- Field, F. J., Born, F., & Mathur, S. N. (1997). Effect of micellar p-sitosterol on cholesterol metabolism in CaCo-2 cells. *Journal of Lipid Research*, 38, 348-360.
- Finkle, W. D., Greenland, S., Ridgeway, K. G., Adams J. L., Frasco, M. A., Cook, M. B., . . . Hoover, R. N. (2014). Increase risk of non-fatal myocardial infarction following testosterone therapy prescription in men. *PLoS One*, 9.
- Hamden, K., Carreau, S., Ayadi, F., Masmoudi, H., & Elfeki, A. (2009). Inhibitory effect of estrogens, phytoestrogens, and caloric restriction on oxidative stress and hepato-toxicity in aged rats. *Biomedical and Environmental Sciences*, 22, 381-387.
- Hedelin, M., Klint, A., Chang, E. T., Bellocco, R., Johansson, J. E., Andersson, S. O., . . . Balter, K. A. (2006). Dietary phytoestrogen, serum enterolactone and risk of prostate cancer: the Cancer Prostate Sweden Study (Sweden). *Cancer Causes and Control*, 17, 169-180.
- Isidori, A. M., Giannetta, E., Greco, E., Gianfrills, D., Bonifacio, V., Isidori, A., . . . Fabbrì, A. (2005). Effects of Testosterone on body composition, bone metabolism and serum lipid profile in middle-aged men: a meta-analysis. *Clinical Endocrinology*, 63, 280-293.
- Lazarov, O., Mattson, M. P., Peterson, D. A., Pimplikar, S. W., & van Praag, H. (2010). When neurogenesis Encounters aging and disease. *Trends in Neurosciences*, 33, 569-579.
- Manasathein, A. (2001). *Comparison of the effects of RED KWO KREUR (Butea superba Roxb.) from two different areas on heart, liver, kidney, adrenal gland and blood components of male Albino rats (Rattus norvegicus)* (Master's thesis, Suranaree University of Technology, Nakon Ratchasima, Thailand).
- Morito, K., Hirose, T., Kinjo, J., Hirakawa, T., Okawa, M., Nohara, T., . . . Masamune, Y. (2001). Interaction of Phytoestrogens with Estrogen Receptors α and β . *Biological and Pharmaceutical Bulletin*, 24, 351-356.

- Morley, J. E., Kaiser, F. E., Perry, H. M., Patrick, P., Morley, P. M., Stauber, P. M., . . . Garry, P. J. (1997). Longitudinal changes in testosterone, Luteinizing hormone, and follicle-stimulating hormone in healthy older men. *Metabolism Clinical and Experimental*, 46, 410-413.
- Mortensen, A., Breinholt, V., Dalsgaard, T., Frandsen, H., Lauridsen, S., Laigaard, J., . . . Larsen, J-J. (2001). 17 β -Estradiol but not the phytoestrogen naringenin attenuates aortic cholesterol accumulation in WHHL rabbits. *Journal of Lipid Research*, 42, 834-843.
- Mu, Y., & Gage, F. H. (2011). Adult hippocampal neurogenesis and its role in Alzheimer's disease. *Molecular Neurodegeneration*, 85, 1-9.
- Ogborn, M. R., Nrrschmann, E., Weiler, H., Lesweick, D., & Bankovic-Calic, N. (1999). Flaxseed ameliorates interstitial nephritis in rat polycystic kidney disease. *Kidney International*, 55, 417-423.
- Payanglee, K., Saleh, F., Wongtawatchai, T., Nuanplab, S., & Radenahmad, N. (2016). Young coconut juice prevents neuronal cell death via ChAT and NMDAR1 neurotransmitters and estrogen receptors in hippocampus and prefrontal cortex of ovariectomized rats. *The Anatomical Record*, (submitting).
- Pilsáková, L., Riečanský, I., & Jagla, F. (2010). The Physiological actions of isoflavone phytoestrogens. *Physiological Research*, 59, 651-664.
- Prachayasakul, W., Chattipakorn, N., & Chattipakorn, S. C. (2011). Effects of estrogen in preventing neuronal insulin resistance in hippocampus of obese rats are different between genders. *Life Science*, 89, 702-707.
- Radenahmad, N., Saleh, F., Sawangjaroen, K., Rundorn, W., Withyachumnarnkul, B., & Connor, J. R. (2009). Young coconut juice significantly reduces histopathological changes in the brain that is induced by hormonal imbalance: A possible implication to postmenopausal women. *Histology and Histopathology*, 24, 667-674.
- Radenahmad, N., Saleh, F., Sawangjaroen, K., Vongvatcharanon, U., Subhadhirasakul, P., Rundorn, W., . . . Connor, J. R. (2011). Young coconut juice, a potential therapeutic agent that could significantly reduce some pathologies associated with Alzheimer's disease: novel findings. *British Journal of Nutrition*, 105, 738-746.
- Radenahmad, N., Sayoh, I., Saleh, F., Sawangjaroen, K., Subhathirasakul, P., Boonyoung, P., . . . Mitranun, W. (2012). Young coconut juice can accelerate the healing process of cutaneous wounds. *BMC Complementary and Alternative Medicine*, 12, 1-10.
- Radenahmad, N., Sawangjaroen K., Mitranun W., Sayoh I. (2016) Beneficial effects of young coconut juice feeding on the lipid, renal and liver profiles, in ovariectomized rats: Preliminary novel findings. *Songklanagarinn Journal of Science and Technology*, 38(1), 57-65
- Radenahmad, N., Suwansa-ard, S., & Sayoh, I. (2015). Young coconut juice accelerates cutaneous wound healing by downregulating macrophage migration inhibitory factor (MIF) in ovariectomized rats: Preliminary novel findings. *Songklanakarinn Journal of Science and Technology*, 37, 417-423.
- Radenahmad, N., Vongvatcharanon, U., Withyachumnarnkul, B., & Connor, J. R. (2006). Serum levels of 17 β -estradiol in ovariectomized rats fed young-coconut-juice and its effect on wound healing. *Songklanakarinn Journal of Science and Technology*, 28, 897-910.
- Rattanaburee, P., Amnuakit, T., Radenahmad, N., & Puripattanavong, J. (2014). Phytochemical study and its quantity and quality of fresh and freeze-dried young coconut juice (*Cocos nucifera* L.). *Advanced Materials Research*, 884-885, 490-493.
- Rosario, E. R., Carroll, J., & Pike, C. J. (2010). Testosterone regulation of Alzheimer-like neuropathology in male 3xtg-ad mice involves both estrogen and androgen pathways. *Brain Research*, 1359, 281-290.
- Santoso, U., Kubo, K., Ota, T., Tadokoro, T., & Maekawa, A. (1995). Nutrient composition of *kopyor* coconuts (*Cocos nucifera* L.). *Food chemistry*, 57, 299-304.
- Sharpe, R. M. (1998). The roles of Oestrogen in the Male. *Trends in Endocrinology and Metabolism*, 9, 371-377.
- Skullerud, K. (1985). Variations in the size of the human brain. Influence of age, sex, body length, body mass index, alcoholism, Alzheimer changes, and cerebral atherosclerosis. *Acta Neurologica Scandinavica Supplementum*, 102, 1-94.
- Soronen, P., Laiti, M., Torn, S., Harkonen, P., Patrikainen, L., Li, Y., . . . Vihko, P. (2004). Sex steroid hormone metabolism and prostate cancer. *The Journal of Steroid Biochemistry and Molecular Biology*, 92, 281-286.
- Sosic-Jurjevic, B., Filipovic, B., Ajdznovic, V., Brkic, D., Ristic, N., Stojanoski, M. M., . . . Seknlic, M. (2007). Subcutaneously administered genistein and daidzein decrease serum cholesterol and increase triglyceride levels in male middle-age rats. *Experimental Biology and Medicine*, 323, 1222-1227.
- Velasquez, M. T., & Bhatena, S. J. (2001). Dietary phytoestrogens: A possible role in renal disease protection. *American Journal of Kidney Disease*, 37, 1056-1068.
- White, L. R., Petrovitch, H. H., Ross, G. W., Masaki, K., Hardman, J., Nelson, J., . . . Markesbery, W. (2000). Brain aging and midlife tofu consumption. *Journal of the American College of Nutrition*, 19, 242-255.
- Yusuh, M., Phochanukoon, N., Radenahmad, N., Eksom tramate, M., Ruangsri, P., Chantanasuksilpa, A., & Reungchaumratkul, A. (2010). Changes of condyle cartilage in orchidectomized rats fed with young coconut juice: Novel preliminary findings. *Songklanakarinn Journal of Science and Technology*, 32, 333-339.