

Original Article

## *Streptococcus iniae* infection in cultured Asian sea bass (*Lates calcarifer*) and red tilapia (*Oreochromis* sp.) in southern Thailand

Naraid Suanyuk<sup>1\*</sup>, Nirut Sukkasame<sup>2</sup>, Nopparat Tanmark<sup>1</sup>, Terutoyo Yoshida<sup>3</sup>, Toshiaki Itami<sup>3</sup>,  
Ronald L. Thune<sup>4</sup>, Chutima Tantikitti<sup>1</sup> and Kidchakan Supamattaya<sup>1</sup>

<sup>1</sup> Aquatic Animal Health Research Center, Department of Aquatic Science, Faculty of Natural Resources,  
Prince of Songkla University, Hat Yai, Songkhla, 90110 Thailand.

<sup>2</sup> Aquaculture Program, Faculty of Agricultural Technology,  
Phuket Rajabhat University, Phuket, 83000 Thailand.

<sup>3</sup> Department of Biological Production and Environmental Science, Faculty of Agriculture,  
University of Miyazaki, 1-1, Gakuen Kibanadai-Nishi, Miyazaki-shi, 889-2192 Miyazaki Prefecture, Japan.

<sup>4</sup> Department of Pathobiological Sciences, College of Veterinary Medicine, and Veterinary Science,  
Agricultural Research Center, Louisiana State University, Baton Rouge 70803, USA.

Received 17 September 2008; Accepted 13 July 2010

### Abstract

Streptococcal infections are becoming an increasing problem in aquaculture and have been reported worldwide in a variety of fish species. Here we describe the isolation and characterization of *Streptococcus iniae* from Asian sea bass (*Lates calcarifer*) and red tilapia (*Oreochromis* sp.) cultured in southern Thailand. Conventional and rapid identification systems, as well as the polymerase chain reaction (PCR), were used to determine that the isolate was *S. iniae*. The virulence of this *S. iniae* was higher in Asian sea bass than in red tilapia, as shown by the 10 day-LD<sub>50</sub> in Asian sea bass and red tilapia, being 1.08x10<sup>4</sup> and 1.14x10<sup>7</sup> CFU, respectively. Histopathological changes in Asian sea bass are more severe than those observed in red tilapia. The changes can be found in several organs including liver, pancreas, heart, eye and brain. Histopathological findings included cellular necrosis, infiltration of lymphocytes and granuloma formation in the infected organs.

**Keywords:** *Streptococcus iniae*, Asian sea bass, Tilapia, pathogenicity

### 1. Introduction

Aquaculture is an important food producer in Thailand. At present more than ten species of fish are being cultured, with Nile tilapia (*Oreochromis niloticus*) and Asian sea bass (*Lates calcarifer*) are in the top ten species produced in Thailand (Department of Fisheries, 2007). The species with the highest economic importance in Thailand are

marine shrimp, tilapia, Asian sea bass and grouper. However, the success of any aquaculture species may be impeded by the prevalence of infectious diseases, especially bacterial diseases, which causes large losses that are a threat to the fish farmers.

Streptococcosis is a major disease in humans as well as other terrestrial animals. In aquaculture, streptococcosis of fish is a generic term used to designate similar but different diseases in any one of at least six different species of Gram-positive cocci, including *Streptococcus*, *Lactococcus*, and *Vagococcus*. The principal pathogenic species responsible for these streptococcal infections are *S. parauberis*, *S. iniae*,

\* Corresponding author.  
Email address: [naraid.s@psu.ac.th](mailto:naraid.s@psu.ac.th)

*S. difficilis*, *L. garvieae*, *L. piscium* and *V. salmoninarum* (Mata *et al.*, 2004b). *S. iniae* (synonym: *S. shiloi*) was first described in captive Amazon freshwater dolphins (*Inia geoffrensis*) (Pier and Madin, 1976). Subsequently, the bacterium was found in various cultured fish stocks, especially hybrid tilapia (*O. niloticus* x *O. aureus*) (Al-Harbi, 1994; Perera *et al.*, 1994), barramundi (*Lates calcarifer*) (Bromage *et al.*, 1999) and red drum (*Sciaenops ocellatus*) (Eldar *et al.*, 1999). Clinical signs of *S. iniae* infection in fishes vary among species, but the most common signs include the loss of equilibrium, unilateral or bilateral exophthalmia, eye opacity, haemorrhage at the base of the fins, and darkening of the skin (Perera *et al.*, 1994; Bromage *et al.*, 1999; Eldar *et al.*, 1999; Colorni *et al.*, 2002).

Tilapia and Asian sea bass are cultured in Asia and the Pacific and are expanding production every year (De Silva *et al.*, 2004; Sugiyama *et al.*, 2004). In May 2003 and December 2004, mortalities in Asian sea bass and red tilapia cultured in cages were observed in southern Thailand. Bacterial culture from moribund fish found pure colonies of Gram-positive cocci that were catalase negative. In this study, we describe the phenotypic characteristic and pathogenicity of *S. iniae*, the causative agent responsible for the mortalities of Asian sea bass and red tilapia in southern Thailand.

## 2. Materials and Methods

### 2.1 Fish epizootics

Mortalities of Asian sea bass from an affected commercial farm in Surat Thani and a red tilapia farm in Nakhon Si Thammarat province were observed in May 2003 and December 2004, respectively. Clinical signs of the infected fish were recorded and samples from brain, kidney and haemorrhaged skin tissues of Asian sea bass and red tilapia displaying clinical signs of the disease were cultured on tryptic soy agar (TSA: Merck, Germany) and incubated at 35°C for 24-48 h. During the disease outbreaks, the water quality parameters i.e., salinity, pH and alkalinity were analyzed by standard methods (Boyd and Tucker, 1992; APHA *et al.*, 1998).

### 2.2 Phenotypic characterization of bacterial isolates

Ten bacterial isolates selected from almost pure colonies on TSA were tested using Gram-staining and the

catalase test. Isolates of catalase negative and Gram-positive cocci were inoculated onto TSA and incubated overnight to obtain a pure culture. Purified bacterial cells were inoculated into tryptic soy broth (TSB: Merck, Germany) supplemented with 15% glycerol and stored at -70°C.

Biochemical characteristic of the ten pure isolates were determined using the API 20 STREP system (bioMérieux®, France) according to the manufacturer's instructions. The bacteria were further characterized using the oxidase test and the haemolytic reaction on blood agar base (Merck, Germany) supplemented with 5% defibrinated sheep blood. The CAMP reaction of the isolates was determined using the conventional diffusion test (Gase *et al.*, 1999). Bacterial growth on bile-esculin agar (40% bile) was tested using the method of Chuard and Reller (1998) and the effect of temperature, pH, and NaCl concentration on growth was determined with brain heart infusion broth (Merck, Germany) using a modified method of Al-Harbi (1994). The Lancefield group antigens of the streptococcal isolates were determined using a Slidex Strepto-kit to group streptococci in groups A, B, C, D, F and G (bioMérieux, France). The conventional, API 20 STREP and Slidex strepto-kit tests were quality controlled and validated using two known isolates, *S. iniae* (Japan isolate) and group B *S. agalactiae* Culture Collection for Medical Microorganisms, Department of Medical Sciences, Thailand (DMST)17129. The classification method used to classify the bacterial genus and species was as described in Bergey's Manual of Systematic Bacteriology (Hardie, 1986) and the APILAB PLUS program (bioMérieux, France).

### 2.3 Polymerase chain reaction (PCR) assay

Nucleic acid was extracted from ten *S. iniae* isolates and the reference strains by alkaline lysis, followed by phenol/chloroform extraction using standard procedures (Duremdez *et al.*, 2004). The target gene and oligonucleotide primer sets used for *S. iniae* detection in the PCR assay are shown in Table 1. All primers were obtained from Operon Biotechnologies, Cologne, Germany. All DNA amplifications were performed according to the methods described for the detection of specific sequences in the 16S rRNA gene (Zlotkin *et al.*, 1998) and the lactate oxidase-encoding gene (*lctO*) of *S. iniae* (Mata *et al.*, 2004a). Amplification of target DNA was performed using a PTC-100™ thermal cycler (MJ Research Inc., USA) using the *S. iniae* reference strains as positive controls and *S. pyogenes* DMST17338, *L. lactis*

Table 1. Primer sequences used for PCR assay.

Primer pair	Sequences (5' to 3')	Target gene	PCR amplicon (bp)	Reference
Sin-1 Sin-2	CTAGAGTACACATGTACT(AGCT)AAG GGATTTTCCACTCCCATTAC	16S rRNA	300	Zlotkin <i>et al.</i> (1998)
LOX-1 LOX-2	AAGGGGAAATCGCAAGTGCC ATATCTGATTGGGCCGTCTAA	<i>lctO</i>	870	Mata <i>et al.</i> (2004a)

TISTR1401, *L. garvieae* FK040708, *Enterococcus faecium* DMST18565 and *Staphylococcus aureus* ATCC25923 as negative controls. The DNA molecular weight markers were a 100-bp DNA ladder (New England Biolabs, USA).

## 2.4 Antibiotic sensitivity

Antibiotic sensitivity patterns were determined using the disc diffusion method (NCCLS, 2002) on Mueller Hinton agar (Merck, Germany). The tests were conducted on ten *S. iniae* isolates from Asian sea bass and red tilapia using standard antibiotic discs (Oxoid, England). The *S. iniae* reference strain was used as a control.

## 2.5 Infectivity trials and histopathology

Healthy red tilapia and Asian sea bass with an average weight of 40-45 g were maintained in three ton fiber glass tanks with aeration. A sample of the potential experimental fish was examined and determined to be pathogenic bacteria free. They were acclimated two weeks before the infectivity test. During the acclimation period, the red tilapia and Asian sea bass were fed daily using commercial feed and fresh fish flesh, respectively.

Relative virulence of the *S. iniae* isolates from diseased Asian sea bass (PSU-AAHRC-ST33.3) and red tilapia (PSU-AAHRC-ST67) were assayed by determining the 10-day lethal dose ( $LD_{50}$ ) (Reed and Muench 1936, Evans *et al.*, 2002). Experimental fish were given an intraperitoneal injection with 0.1 ml of a bacterial suspension at concentrations ranging from  $10^1$  to  $10^9$  CFU/ml using 10 fish/dose/aquarium. A control group of 10 fish were similarly inoculated with sterile 0.85% NaCl. The water temperature was 26-28°C. The mean  $LD_{50}$  was determined using the simplified method of Reed and Muench (1936). Tissue samples from moribund fish were collected and the bacterial cells were re-isolated from these tissues on blood agar to confirm the cause of death. In addition, samples of liver, kidney, brain, and eye from experimentally infected fishes were prepared for histological studies using the standard methods of Humason (1979) and examined using light microscopy.

## 3. Results

### 3.1 Fish epizootics

Naturally infected Asian sea bass exhibited typical clinical signs of streptococcal infection, including loss of equilibrium, exophthalmia and opacity of the eye, loss of appetite, lethargy and irregular movement. Some fish showed darkening of the skin, emaciation, and petechiae on the operculum and proximal margins of the pectoral fins. Accumulation of fluid in the peritoneal cavity and hemorrhaging of the internal organs, with pale livers and enlarged spleens, were also found. With red tilapia, the disease signs of the streptococcal infection were similar to those observed in

infected Asian sea bass, except that body depigmentation was found. Water quality parameters during the disease outbreak in Asian sea bass were as follows: salinity 2.7 ‰, pH 7.72 and alkalinity 100 mg/l. Water quality during the red tilapia epizootics were as follows; salinity 0 ‰ and the pH ranged from 7.56-8.41.

### 3.2 Phenotypic characteristics

Bacterial isolates from infected fish were identified as *S. iniae* by conventional phenotypic characteristics, the API 20 STREP system, and Slidex Strepto-kit. Isolates obtained from Asian sea bass and red tilapia were similar in phenotypic and biochemical characteristics (Table 2), being Gram-positive cocci; catalase and oxidase negative; beta-haemolytic on blood agar (5% sheep blood); no growth on bile esculin agar (40% bile), no growth in 6.5-10% NaCl and pH 9.6, with a high temperature range of 40-45°C. No agglutination was found when the isolates were tested for the Lancefield serogroup using Slidex Strepto-kit. Rapid API 20 STREP system resulted in profile numbers of 4 7 7 3 1 1 7 and 4 5 6 3 1 1 7, corresponding to an unacceptable and acceptable match to *S. dysgalactiae* subsp. *equisimilis*. The API 20 STREP system and Slidex Strepto-kit successfully identified the group B *S. agalactiae* DMST17129 control isolate.

### 3.3 PCR assay

The PCR assay resulted in the amplification of 300 bp band (16S rRNA) and 870 bp band (*lctO*) that were detected in all *S. iniae* isolated from the present study including the *S. iniae* reference strain. Examples of the amplified band are shown in Figure 1 (lanes 3 and 4). No amplification occurred when phylogenetically related bacteria was used as the template.

### 3.4 Antibiotic sensitivity

This *S. iniae* was sensitive to ten antibiotics, including ampicillin, chloramphenicol, erythromycin, gentamicin, nitrofurantoin, norfloxacin, oxytetracycline, penicillin G, sulphamethoxazole/trimethoprim and trimethoprim. The isolates were resistant to nalidixic acid and oxolinic acid. Similar results, except for oxytetracycline, were also obtained for the reference *S. iniae* strain.

### 3.5 Infectivity trials and histopathology

Experimentally inoculated Asian sea bass and red tilapia exhibited 0-60 % mortality within 10 days. Disease signs due to experimental infection were similar to those of infected fish found in commercial fish farms. Examples of some clinical sign are shown in Figure 2-3, although some fish died without showing clinical signs. Inoculation and reisolation of *S. iniae* from dead fish established the organism as pathogenic for the fish (Figure 4-5) and confirmed

Table 2. *S. iniae* isolated from infected red tilapia and Asian sea bass. Comparison of phenotypic characteristics of the isolates to the reference strains

Test	Present isolates		<i>S. iniae</i> <sup>1</sup>	Test	Present isolates		<i>S. iniae</i> <sup>1</sup>
Fish	Tilapia (n=6)	Sea bass (n=4)	-	Hippurate	-	-	-
Gram staining reaction	+	+	+	Esculin	+	+	+
Cell morphology	Cocci	Cocci	Cocci	Arginine	+	+	+
Catalase production	-	-	-	Pyrrolidonyl arylamidase	+	+	+
Oxidase production	-	-	-	$\alpha$ -Galactosidase	+	-	+
Voges Proskauer	-	-	-	$\beta$ -Glucuronidase	+	+	+
CAMP	+	+	+	$\beta$ -Galactosidase	+	-	+
Haemolysis (5% sheep RBC)	$\beta$	$\beta$	$\gamma$	Alkaline phosphatase	+	+	+
Serogroup <sup>2</sup>	non	non	non	Leucine aminopeptidase	+	+	+
Growth on/in:							
- Brain heart infusion	+	+	+	Acid production from:			
- Tryptic soy agar	+	+	+	- D-Ribose	+	+	+
- Blood agar	+	+	+	- L- Arabinose	-	-	-
- Bile esculin agar (40%bile)	-	-	-	- Mannitol	+	+	+
- 6.5% NaCl	-	-	-	- D-Sorbitol	-	-	-
- 8.0% NaCl	-	-	-	- D-Lactose	-	-	-
- 10.0%NaCl	-	-	-	- D-Trehalose	+	+	+
- pH 9.6	-	-	-	- Inulin	-	-	-
- temp 35°C	+	+	+	- D-Raffinose	-	-	-
- temp 40°C	-	-	-	- AMD	+	+	+
- temp 45°C	-	-	-	- Glycogen	+	+	+

<sup>1</sup>*S. iniae* Japan isolate; <sup>2</sup>reacts with group A, B, C, D, F and G;  
n, reflects number of isolates

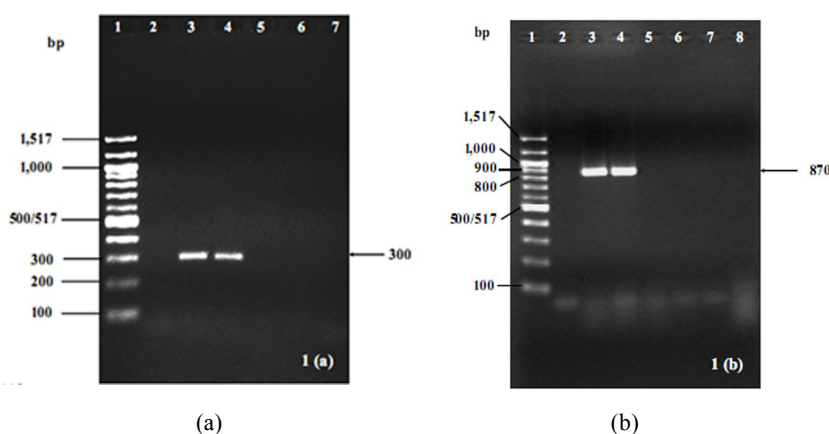


Figure 1. Agarose gel showing amplification products of *S. iniae* compared to other strains. (a) PCR amplification products of *S. iniae* generated with primer sets Sin-1/Sin-2. Lane1, 100-bp molecular standard size ladder; Lane 2, negative control (no template); Lane 3, *S. iniae* reference strain; Lane 4, fish isolate; Lane 5, *S. pyogenes* DMST17338; Lane 6, *L. lactis* TISTR1401; Lane 7, *L. garvieae* FK040708. (b) PCR amplification products using *S. iniae* generated with primer set LOX-1/LOX-2. Lane1, 100-bp molecular size ladder; Lane 2, negative control (DDW); Lane 3, *S. iniae* reference strain; Lane 4, fish isolate; Lane 5, *S. pyogenes* DMST17338; Lane 6, *L. lactis* TISTR1401; Lane 7, *E. faecium* DMST18565; Lane 8, *Staph. aureus* ATCC25923.

Koch's postulates. Experimental challenge of red tilapia and Asian sea bass resulted in a 10 day-LD<sub>50</sub> of 1.14x10<sup>7</sup> and 1.08x10<sup>4</sup> CFU, respectively. No mortality occurred in the control groups.

Histopathological changes in Asian sea bass are more severe than those observed in red tilapia. The changes can be found in several organs including liver, pancreas, heart, eye and brain. The liver tissue exhibited a dilation of hepatic



Figure 2. Gross photograph of red tilapia infected with *S. iniae* by experimental infection showing depigmentation and eye opacity.



Figure 3. Gross photograph of Asian sea bass infected with *S. iniae* by experimental infection showing haemorrhage and bilateral exophthalmic eye.

sinusoids and lymphocytic infiltration. Hepatocytes showed a high level of vacuolization, degeneration, and focal necrosis (Figure 6-7). Pancreatic tissues showed degeneration of acinar cells and a loss of zymogen granules (Figure 6). Granuloma formation and degeneration of eye tissue were observed in Asian sea bass (Figure 8). Large numbers of infiltrating lymphocyte and macrophage centers, as well as an extended epicardium, were apparent in the hearts of both Asian sea bass and red tilapia (Figure 9-10). Brain tissues from infected fish showed lymphocytic infiltration around the infected areas (Figure 11).

#### 4. Discussion

Haemolytic streptococci produce a variety of diseases in man and/or animals (Rotta, 1986). The results obtained in this study suggest that the present isolates are biochemically and physiologically similar to those isolated in previous studies (Perera *et al.*, 1994; Bromage *et al.*, 1999; Colorni *et al.*, 2002). The rapid API 20 STREP system successfully identified the *S. agalactiae* DMST17129 control isolate but failed to identify the experimental isolates. This agrees with the observations of Bromage *et al.* (1999) who found an un-

acceptable match to *S. equisimilis* when using the APILAB PLUS program. Serological tests showed no agglutination when the isolates were tested for the Lancefield serogroups, A, B, C, D, F and G, using the Slidex Strepto-kit. This agrees with Rotta (1986) where the *S. iniae* antigen does not react with group-specific antisera A-V but strongly reacts with rabbit hyper-immune anti-sera against *S. iniae*.

Our PCR analysis allowed identification of the strains as *S. iniae* using primers designed for the 16S rRNA gene, which amplified a specific 300 bp DNA fragment from our isolates from diseased fish, as well as the *S. iniae* reference strain. Because Mata *et al.* (2004a) reported a similar 300 bp product from *S. difficilis* using the same primer set, we confirmed the identification of *S. iniae* by performing a second PCR using a primer set designed against the *lctO* gene (Mata *et al.* 2004a). The specific 870 bp DNA fragment was amplified from our isolates, as well as the *S. iniae* reference strain, confirming the identification as *S. iniae*.

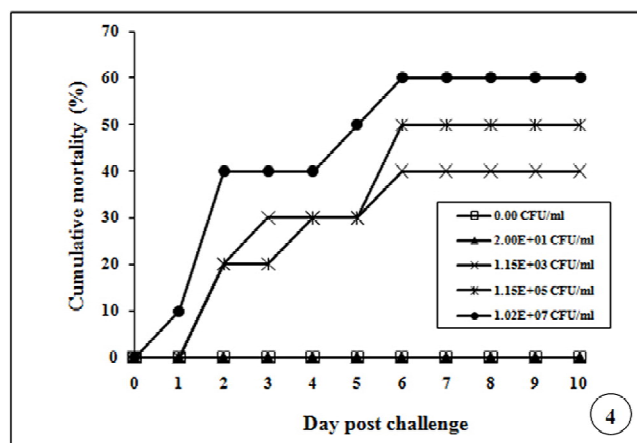


Figure 4. Mortality rate of Asian sea bass intraperitoneally injected with various concentration of *S. iniae* PSU-AAHRC-ST33.3.

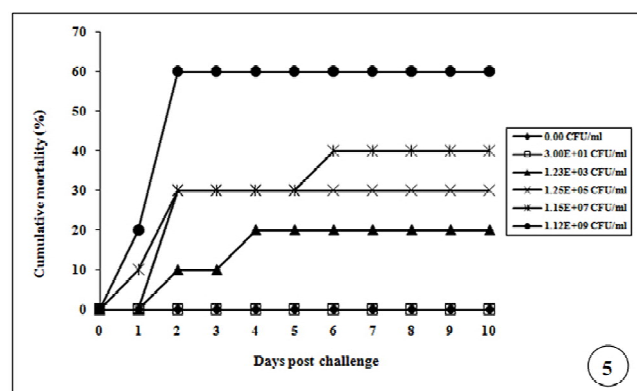


Figure 5. Mortality rate of red tilapia intraperitoneally injected with various concentration of *S. iniae* PSU-AAHRC-ST67.



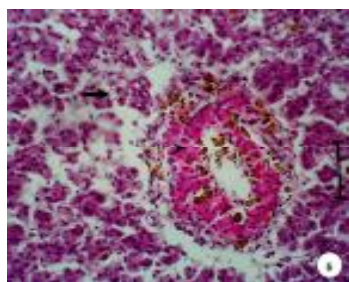


Figure 6. Liver and pancreatic tissue of red tilapia infected with *S. iniae* showing dilation of the hepatic sinusoids, high level of vacuolization (arrow), and focal necrosis. Pancreatic tissue showing degenerated acinar cells (arrow head) and zymogen granules (H&E, Bar = 50 mm).

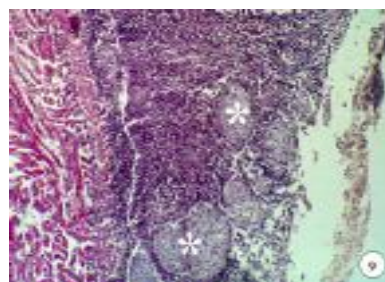


Figure 9. Heart of Asian sea bass infected with *S. iniae* showing extended of epicardium layer and infiltrated with large number of lymphocytes and macrophage center (asterisk) (H&E, Bar = 100 mm).

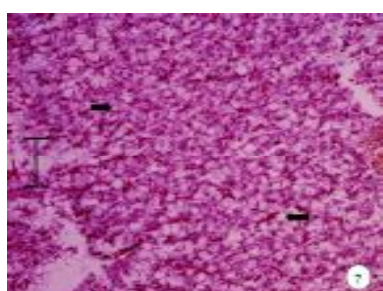


Figure 7. Liver tissue of Asian sea bass infected with *S. iniae* showing highly hepatocytes vacuolization (arrow) (H&E, Bar = 50 mm).

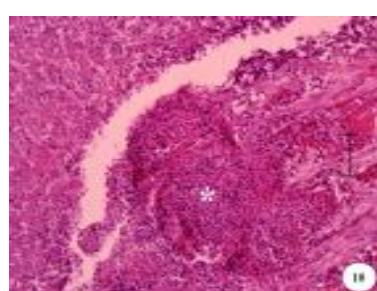


Figure 10. Heart of red tilapia infected with *S. iniae* showing granuloma formation and infiltrated with large number of lymphocytes (asterisk) (H&E, Bar = 50 mm).

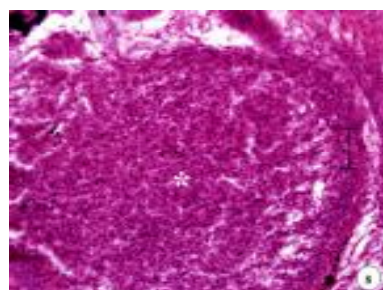


Figure 8. Eye tissue of Asian sea bass infected with *S. iniae*, showing granuloma formation and degeneration of eye tissue (asterisk) (H&E, Bar = 50 mm).

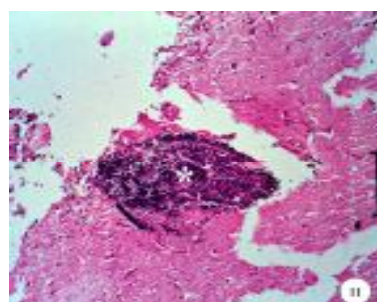


Figure 11. Brain tissue of Asian sea bass infected with *S. iniae*, showing lymphocytic infiltration (asterisk) (H&E, Bar = 100 mm).

The RAPD method has been used extensively to show variation among *S. iniae* isolates (Bachrach *et al.*, 2001; Colorni *et al.*, 2002). We attempted RAPD to discriminate between *S. iniae* isolates recovered from Asian sea bass and red tilapia. However, the RAPD analysis showed an identical pattern (data not shown) using the primers described previously (Bachrach *et al.*, 2001; Colorni *et al.*, 2002). Further investigation using both RAPD with different primers and amplified fragment length polymorphism (AFLP) may provide more insight into the relationship between these isolates.

Similarly, anti-microbial susceptibility tests confirmed a close phenotypic resemblance between the isolates and

*S. iniae*, except for oxytetracycline. The isolates were similar to those isolated from hybrid tilapia reported by Al-Harbi (1994) and Perera *et al.* (1994), except that the hybrid tilapia strains were resistant to trimethoprim (Al-Harbi, 1994) and ampicillin (Perera *et al.*, 1994).

Clinical signs of streptococcal infections vary between species. Darkening of the skin pigment has been reported in various fish species infected with *Streptococcus* sp. (Rasheed *et al.*, 1985; Bromage *et al.*, 1999; Evans *et al.*, 2000; Shoemaker *et al.*, 2000). Body depigmentation of red tilapia found in this study was similar to those observed in red tilapia infected with *S. agalactiae* (Suanyuk *et al.*, 2005, 2008) and

Nile tilapia infected with rickettsia-like organisms (Chen *et al.*, 1994).

Experimental infection of red tilapia and Asian sea bass demonstrated that *S. iniae* is pathogenic to fish, although the virulence of the red tilapia isolate used in this study was less than the *S. iniae* from tilapia cultured in Texas, which had a 96h-LD<sub>50</sub> of 4.9x10<sup>5</sup> and a 168 h-LD<sub>50</sub> of 3.18x10<sup>5</sup> CFU/ml (Perera *et al.*, 1997). The virulence of the Asian sea bass isolate in this study was similar to the *S. iniae* infection in barramundi cultured in Australia, with a 10-days LD<sub>50</sub> of 3.2x10<sup>4</sup> CFU (Bromage *et al.*, 1999). However, many factors are involved in evaluating virulence, making LD<sub>50</sub> comparisons difficult to evaluate e.g. water temperature or poor environmental conditions will stress animals resulting in a decline in the ability of their immune systems to respond with an increase in vulnerability to invading pathogen (Anderson, 1990; Baya *et al.*, 1990; Cheng and Chen, 1998).

*Streptococcus iniae* infections in red tilapia and Asian sea bass are systemic infections of the liver, pancreas, heart, eye and brain. The distinct pathology found in Asian sea bass was the infiltration of large numbers of macrophage centers in infected areas such as the heart. Lymphocytic infiltration noted in the brain was similar to reports in tilapia and channel catfish (*Ictalurus punctatus*) infected with *Streptococcus* sp. (Chang and Plumb, 1996). Pathology detected in the brain corresponded to the gross manifestation of neurological signs in both infected red tilapia and Asian sea bass. Vacuolization, degeneration, and necrosis observed in the liver were similar to those observed in tilapia infected with *Streptococcus* sp. (Miyazaki *et al.*, 1984). In addition, changes in the liver resembled pathology found in bullminnows and tilapia infected with group B *Streptococcus* sp. (Rasheed *et al.*, 1985; Suanyuk *et al.*, 2008).

In summary, the present study shows that *S. iniae* has great impact on the Asian sea bass and tilapia cultivation in Thailand. Presently, streptococcosis occurs in various aquaculture areas throughout the country. Further studies on the effects of environmental factors are necessary to assess the damage directly caused by this disease and to evaluate the possible application of streptococcosis vaccines.

## Acknowledgement

This study was supported by Thailand Research Fund, The Royal Golden Jubilee Ph.D. program, to Naraid Suanyuk. Thanks to Sasitorn Jongyotha and Samaporn Jomsawat for their help in the collection of the diseased fish.

## References

- Al-Harbi, A. H. 1994. First isolation of *Streptococcus* sp. from hybrid tilapia (*Oreochromis niloticus* x *O. aureus*) in Saudi Arabia. *Aquaculture*. 128, 195-201.
- Anderson, D. P. 1990. Immunological indicators: Effects of environmental stress on immune protection and disease outbreak. *American Fisheries Society Symposium*. 8, 38-50.
- APHA, AWWA and WEF. 1998. Standard methods for the examination of water and wastewater. American Public Health Association (APHA), American Water Works Association (AWWA), and Water Environment Federation (WEF), Washington D C, 874 p.
- Bachrach, G., Zlotkin, A., Hurvitz, A., Evans, D. L. and Eldar, A. 2001. Recovery of *Streptococcus iniae* from diseased fish previously vaccinated with a *Streptococcus* vaccine. *Applied and Environmental Microbiology*. 67, 3756-3758.
- Baya, A. M., Lupiani, B., Hetrick, F. M., Roberson, B. S., Lukacovic, R., May E. and Poukish, C. 1990. Association of *Streptococcus* sp. with fish mortalities in the Chesapeake Bay and its tributaries. *Journal of Fish Diseases*. 13, 251-253.
- Boyd, C. E. and Tucker, C. S. 1992. Water quality and pond soil analyses for aquaculture. Alabama Agricultural Experiment Station, Auburn University, Alabama, 183 p.
- Bromage, E. S., Thomas, A. and Owens, L. 1999. *Streptococcus iniae*, a bacterial infection in barramundi *Lates calcarifer*. *Diseases of Aquatic Organisms*. 36, 177-181.
- Chang, P. H. and Plumb, J. A. 1996. Histopathology of experimental *Streptococcus* sp. infection in tilapia, *Oreochromis niloticus* (L.), and channel catfish, *Ictalurus punctatus* (Rafinesque). *Journal of Fish Diseases*. 19, 235-241.
- Chen, S. C., Tung, M. C., Chen, S. P., Tsai, J. F., Wang, P. C., Chen, R. S., Lin, S. C. and Adams, A. 1994. Systemic granulomas caused by a rickettsia-like organism in Nile tilapia, *Oreochromis niloticus* (L.), from southern Taiwan. *Journal of Fish Diseases*. 17, 591-599.
- Cheng, W. and Chen, J. C. 1998. Enterococcus-like infections in *Macrobrachium rosenbergii* are exacerbated by high pH and temperature but reduced by low salinity. *Diseases of Aquatic Organisms*. 34, 103-108.
- Chuard, C. and Reller, L. B. 1998. Bile-esculin test for presumptive identification of Enterococci and Streptococci: Effects of bile concentration, inoculation technique, and incubation time. *Journal of Clinical Microbiology*. 36, 1135-1136.
- Colorni, A., Diamant, A., Eldar, A., Kvitt, H. and Zlotkin, A. 2002. *Streptococcus iniae* infections in red sea cage cultured and wild fishes. *Diseases of Aquatic Organisms*. 49, 165-170.
- Department of Fisheries. 2007. Fisheries statistics of Thailand 2005. Technical paper No. 6/2007. Fishery Information Technology Center, Department of Fisheries, Ministry of Agriculture and Cooperatives, 91 p.
- De Silva, S. S., Subasinghe, R. P., Bartley, D. M. and Lowther, A. 2004. Tilapias as alien aquatics in Asia and the Pacific: a review. *FAO Fisheries Technical Paper*. No. 453. FAO, Rome.
- Duremdaz, R., Al-Marzouk, A., Qasem, J. A., Al-harbi A. and

- Gharabally, H. 2004. Isolation of *Streptococcus agalactiae* from cultured silver pomfret, *Pampus argenteus* (Euphrasen), in Kuwait. *Journal of Fish Diseases*. 27, 307-310.
- Eldar, A., Perl, S., Frelie P. F. and Bercovier, H. 1999. Red drum *Sciaenops ocellatus* mortalities associated with *Streptococcus iniae* infection. *Diseases of Aquatic Organisms*. 36, 121-127.
- Evans, J. J., Shoemaker, C. A. and Klesius, P. H. 2000. Experimental *Streptococcus iniae* infection of hybrid striped bass (*Morone chrysops* x *Morone saxatilis*) and tilapia (*Oreochromis niloticus*) by nares inoculation. *Aquaculture*. 189, 197-210.
- Evans, J. J., Klesius, P. H., Gilbert, P. M., Shoemaker, C. A., Al Sarawi, M. A., Landsberg, J., Duremdez, R., Al Marzouk, A., and Al Zenki, S. 2002. Characterization of b-haemolytic Group B *Streptococcus agalactiae* in cultured seabream, *Sparus auratus* L., and wild mullet, *Liza klunzingeri* (Day), in Kuwait. *Journal of Fish Diseases*. 25, 505-513.
- Gase, K., Ferretti, J. J., Primeaux, C. and McShan, W. M. 1999. Identification, cloning, and expression of the CAMP factor gene (*cfa*) of group A streptococci. *Infection and Immunity*. 67, 4725 - 4731.
- Hardie, J. M. 1986. Genus *Streptococcus* Rosenbach 1884, 22<sup>AL</sup>, *In* Bergey's Manual of Systematic Bacteriology (ed. By Sneath, P. H. A., N. S. Mair, M. E. Sharpe and J. G. Holt). Williams & Wilkins, Baltimore, pp. 1043 - 1047.
- Humason, G. L. 1979. Animal tissue techniques. W. H. Freeman and Company, San Francisco, 661 p.
- Mata, A. I., Blanco, M. M., Domínguez, L., Fernández-Garayzábal, J. F. and Gibello, A. 2004a. Development of a PCR assay for *Streptococcus iniae* based on the lactate oxidase (*lctO*) gene with potential diagnostic value. *Veterinary Microbiology*. 101, 109-116.
- Mata, A. I., Gibello, A., Casamayor, A., Blanco, M. M., Domínguez, L. and Fernández-Garayzábal, J. F. 2004b. Multiplex PCR assay for detection of bacterial pathogens associated with warm-water streptococcosis in fish. *Applied and Environmental Microbiology*. 70, 3183-3187.
- Miyazaki, T., Kubota, S. S., Kaige, N. and Miyashita, T. 1984. A histopathological study of streptococcal disease in tilapia. *Fish Pathology*. 19, 167-172.
- NCCLS. 2002. Performance standards for antimicrobial disk and dilution susceptibility tests for bacteria isolated from animals; approved standard second edition. NCCLS document M31-A2. NCCLS, Wayne, Pennsylvania, 80 p.
- Perera, R. P., Johnson, S. K., Collins M. D., and Lewis, D. H. 1994. *Streptococcus iniae* associated with mortality of *Tilapia nilotica* x *T. aurea* Hybrids. *Journal of Aquatic Animal Health*. 6, 335-340.
- Perera, R. P., Johnson, S. K. and Lewis, D. H. 1997. Epizootiological aspects of *Streptococcus iniae* affecting tilapia in Texas. *Aquaculture*, 152, 25-33.
- Pier, G. B. and Madin, S. H. 1976. *Streptococcus iniae* sp. nov., a beta-hemolytic streptococcus isolated from an Amazon freshwater dolphin, *Inia geoffrensis*. *International Journal of Systematic Bacteriology*. 26, 545-553.
- Rasheed, V., Limsuwan, C. and Plumb, J. 1985. Histopathology of bullminnows, *Fundulus grandis* Baird & Girard, infected with a non-haemolytic group B *Streptococcus* sp. *Journal of Fish Diseases*. 8, 65-74.
- Reed, L. J. and Muench, H. 1936. Simple method of estimating fifty percent endpoint. *American journal of hygiene*. 27, 493-497.
- Rotta, J. 1986. Pyogenic Hemolytic Streptococci, *In* Bergey's Manual of Systematic Bacteriology (ed. By Sneath, P. H. A., N. S. Mair, M. E. Sharpe and J. G. Holt). Williams & Wilkins, Baltimore, pp. 1047 - 1054.
- Shoemaker, C. A., Evans, J. J. and Klesius, P. H. 2000. Density and dose: factors affecting mortality of *Streptococcus iniae* infected tilapia (*Oreochromis niloticus*). *Aquaculture*. 188, 229-235.
- Sugiyama, S., Staples, D. and Funge-Smith, S. J. 2004. Status and potential of fisheries and aquaculture in Asia and the Pacific. FAO Regional Office for Asia and the Pacific. RAP Publication 2004/25, 53 p.
- Suanyuk, N., Kangheae, H., Khongpradit, R. and Supamattaya, K. 2005. *Streptococcus agalactiae* infection in Tilapia (*Oreochromis niloticus*). *Songklanakarin Journal of Science and Technology*. 27 (Suppl. 1), 307-319.
- Suanyuk, N., Fanrong, K., Ko, D., Gilbert, G. L. and Supamattaya, K. 2008. Occurrence of rare genotypes of *Streptococcus agalactiae* in cultured red tilapia *Oreochromis* sp. and Nile tilapia *O. niloticus* in Thailand-Relationship to human isolates?. *Aquaculture*. 284, 35-40.
- Zlotkin, A., Hershko, H. and Eldar, A. 1998. Possible transmission of *Streptococcus iniae* from wild fish to cultured marine fish. *Applied and Environmental Microbiology*. 64, 4065-4067.